

ZIBELINE INTERNATIONAL
PUBLISHING

ISSN: 2590-4043 (Online)

CODEN: AEMCDV



RESEARCH ARTICLE

FILTERING ALGORITHMS FOR DE-SPECKLE THE ULTRASOUND IMAGES OF BONE FRACTURE

Muhammad Luqman Muhd Zain*, Wan Faizura Wan Tarmizi, Ruzlaine Ghoni

Faculty of Electrical and Automation Engineering Technology, University College TATI, Teluk Kalong, 24000 Kemaman, Terengganu, Malaysia.

*Corresponding Author Email: muhammadluqman83@hotmail.com

This is an open access article distributed under the Creative Commons Attribution License CC BY 4.0, which permits unrestricted use, distribution, and reproduction in any medium, provided the original work is properly cited.

ARTICLE DETAILS

Article History:

Received 18 September 2020

Accepted 20 October 2020

Available Online 30 October 2020

ABSTRACT

Ultrasound images are popularly known to contain speckle noise that degrades the quality of the images for good and fast interpretation in many areas of medicine, especially for bone fracture detection. This necessitates the need for robust de-speckling techniques for clinical practice. Therefore, a study was carried out to reduce speckle using filtering algorithms such as Wiener, Average, Median and Wavelets. This paper discusses the level of improvement obtained through these filtering algorithms using the peak signal to noise ratio (PSNR) as a measurement tool. The results of our work presented in this paper suggest that the combination of Daubechies–Wiener which we call as a hybrid technique, gave the best performance, which is a new contribution in this field. This de-speckling algorithm can be further developed and evaluated at a larger scale.

KEYWORDS

Interpretation, medicine, techniques, algorithms, Daubechies–Wiener

1. INTRODUCTION

Over the years, the field of radiology has grown as a result of advances in imaging technology. The most common imaging modalities used in orthopaedics are fluoroscopy (projection X-rays), computed tomography (CT) and magnetic resonance imaging (MRI). However, these techniques use ionizing radiation, which raises important safety concerns for both patients and medical practitioners. Hence, it is important to find out and develop an alternative method for long bone fracture detection. The advantages of ultrasound imaging over Conventional radiography (X-ray), computed tomography (CT) and magnetic resonance imaging (MRI) are reported as being painless, does not use ionizing radiation, is less expensive, can be performed real time, needs no special environment and is clinically readily accessible. However, nonlinear characteristics of ultrasound, low signal-to-noise ratio, speckles, and reverberations make it exceedingly difficult to accurately and reliably determine the bone fracture (Heiner and McArthur, 2010).

A group researcher reported that out of 234 suspected apophyseal fractures in adolescents, 80 were detected by radiography and 97 by ultrasound (Lazovic et al., 1996). Rathfelder and Paar described good results in the first substantial study on the possible application of ultrasound in the diagnosis of fractures in children (Rathelder and Paar, 1995). A group researchers suggested that ultrasound assessment without radiography should be used in particular cases such as suspected bulge fractures or mildly displaced, simple fractures of the long bones of the forearm, humerus, femur, lower leg and clavicle (Hubner et al., 2000). Evaluation by ultrasound for fracture detection has the advantage of

immediate clinical correlation and can be made by people with minimal training in the use of ultrasound (Noble et al., 2003; Marshburn et al., 2004). In addition, ultrasound images have the advantage of being non-invasive, portable, versatile, low cost and not requiring ionizing radiations. However, ultrasound images in general are complex due to data composition, which can be described in terms of speckle information (Yap et al., 2006). Upon visual inspection, speckle noise consists of a relatively high grey level intensity, qualitatively ranging between hyperechoic (bright) and hypoechoic (dark) domains (Friedland and Adam, 1989). Various researchers have used different filtering algorithms to improve the quality of ultrasound images.

2. MATERIAL AND METHODS

A bone fracture was captured using ultrasound equipment. Bone is a highly heterogeneous and anisotropic living tissue with composition and structure varying, depending on the skeletal site, function, age, sex and type of vertebrate species (Zain et al., 2009). Also, bone is a hard matrix of calcium salts deposited around protein fibers with ideal hardness, moderate elasticity, limited plasticity and brittleness for different body part movements. The quality of the ultrasound images depends on the types of probe and how it is positioned, the experience of the examiner and the features of the ultrasound scanner itself. The images used in this study were obtained which used an Ultrasound Scanner of 3.5–9.5 MHz with a linear probe (Ultrasound images on bone fracture, Aloka Holding Europe Ag, Switzerland).

Quick Response Code



Access this article online

Website:

www.actaelectronicamalaysia.com

DOI:

10.26480/aem.02.2020.40.42

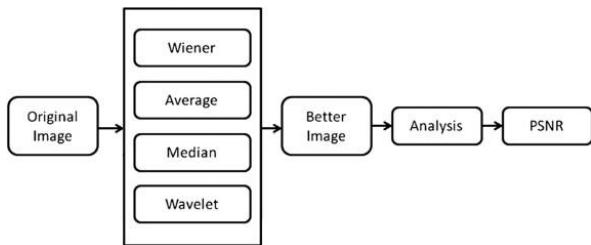


Figure 1: Process flow of filtering process.

Figure 1 shows the process flow of the speckle reduction process. The five techniques were examined and compared to determine which one would be able to reduce speckle noise in ultrasound images. The filtering was implemented using MATLAB (The Mathworks Inc). A total of 11 ultrasound images of bone fracture were used in this experiment. The original ultrasound images were processed separately using Wiener, Average, Median, Anisotropic Diffusion and Wavelets (Biorthogonal 6.8, Daubechies 10, Haar and Symlets 8) respectively, and the output images were generated. From the output images, the differences of images were analysed based on the peak signal-to-noise ratio (PSNR).

3. RESULTS AND DISCUSSION

The results of ultrasound image filtering carried out separately using Wiener, Average, Median, first, then, Wavelets (Biorthogonal 6.8, Daubechies 10, Haar and Symlets 8) are given in the following.

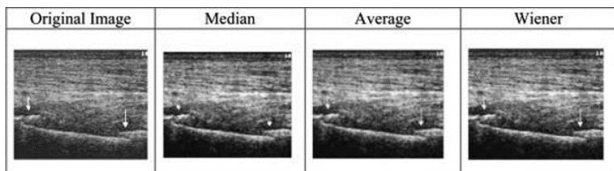


Figure 2: Fibula fracture ultrasound image using Median, Average and Wiener.

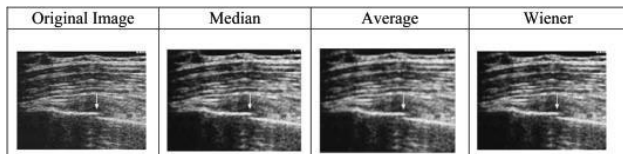


Figure 3: Rib fracture ultrasound image using Median, Average and Wiener.

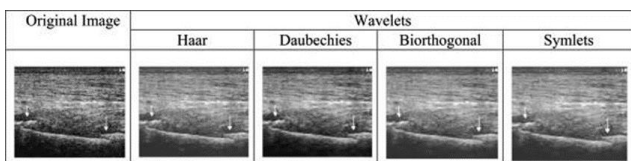


Figure 4: Fibula fracture ultrasound image.

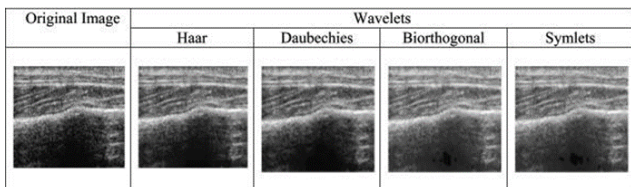


Figure 5: Rib fracture ultrasound image.

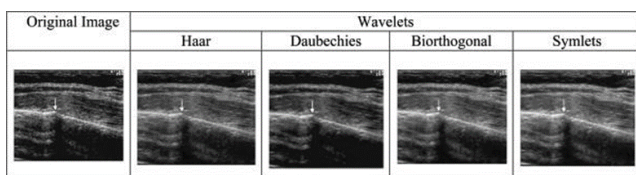


Figure 6: Rib fracture with callus formation ultrasound image.

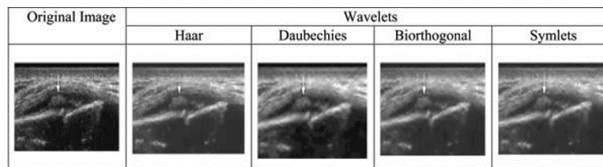


Figure 7: Distal fracture with callus formation

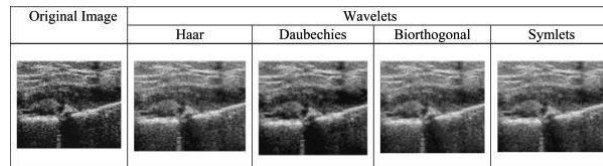


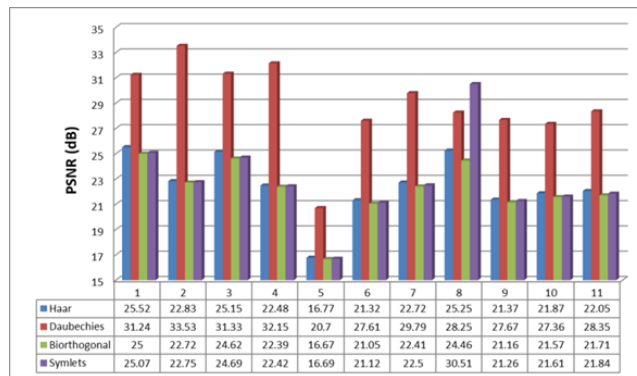
Figure 8. Stress fracture of the tibia with callus formation ultrasound image.

The enhancement of different bone fracture ultrasound images using the Median, Average and Wiener filters are best illustrated by two images of fractures, comprising of fibula and rib as shown in Figure 2 and 3 respectively. An analysis of the images after applying Median, Average and Wiener techniques shows that the Median filtering was able increase the intensity value at a certain point in the image; whilst, the Average filtering was able to the increase the value of pixels but the intensity value was decreased. The Wiener filtering showed a similar trend as the Average filtering.

However, the intensity values of Wiener filtering are higher than that of Average filtering and this resulted in making the images sharper. It was found that amongst the three techniques, Wiener filtering is a better technique in reducing the speckle without fully eliminating the image edges. This is based on visual inspection and histogram analysis. Additional information on the histogram diagrams that was reported by the same authors could be found in (Zain et al., 2009). Figures 4–8 show the enhancement of different bone fracture ultrasound images using the wavelet (Biorthogonal 6.8, Daubechies 10, Haar and Symlets 8) despeckling method. Figure 2 and 4 are Fibula fracture, Figure 3 and 5 are Rib fracture, Figure 6 is Rib fracture with callus formation, Figure 7 is Distal fracture with callus formation, Figure 8 is Stress fracture of the tibia with callus formation. The PSNR values that were obtained for the ultrasound images used shown in Table 1.

Table 1 shows that the best type of wavelet that could be used for speckle reduction in ultrasound images is Daubechies. It gives the highest PSNR value compared with the other type of wavelets. It can be seen that the wavelet-based method gets better results both in terms of speckle reduction and signal detail preservation. The wavelet filter is suitable for removing the speckle in ultrasound images and improving the image qualities as well. In addition, the method is easy to implement and the statistics are easy to estimate and characterize.

Table 1: Comparison of PSNR for different types of wavelet.



Figures 9–13 show the enhancement of different bone fracture ultrasound images using the hybrid combination which involved Wavelet–Median, Wavelet–Average and Wavelet– Wiener.

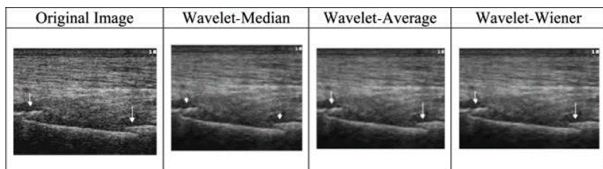


Figure 9: Fibula fracture ultrasound image.

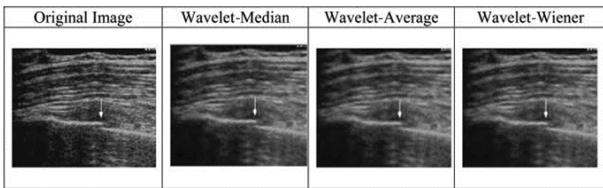


Figure 10: Rib fracture ultrasound image, sample 1.

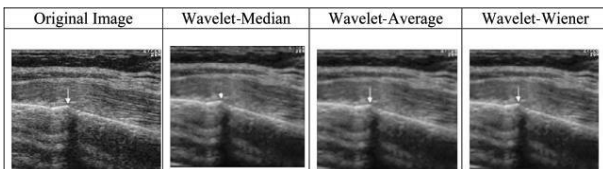


Figure 11: Rib fracture ultrasound image, sample 2.

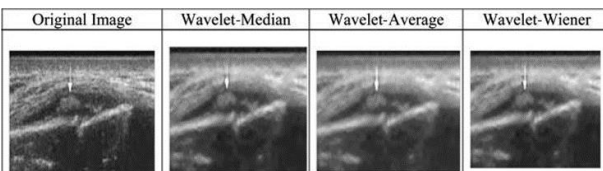


Figure 12: Rib fracture with callus formation ultrasound image.

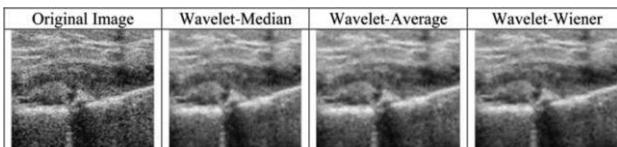
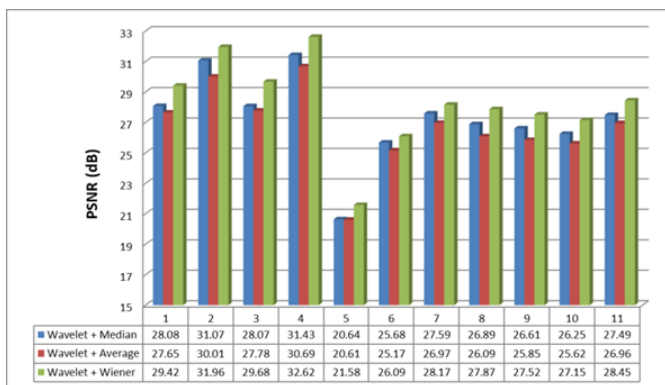


Figure 13: Distal fracture with callus formation.

Table 3 shows the PSNR values of results of hybrid combination which involved Wavelet- Median, Wavelet-Average and Wavelet-Wiener.

Table 2: Comparison of PSNR for Wavelet-Median, Wavelet-Average, Wavelet-Wiener.



From Table 3, it can be seen that the hybrid combination of Wiener with Daubechies wavelet show the best result compared with the other 2 combinations. It gives the highest PSNR value among the combination. However, the results of our work presented in this paper suggest that the combination of Wavelet (Daubechies)-Wiener which we call as Hybrid technique gave the best performance in de-speckle the ultrasound images of bone fracture.

4. CONCLUSIONS

The paper discussed the investigation of speckle reduction of ultrasound images of bone fracture using various types of de-speckling algorithms such as Wiener, Average, Median and Wavelets (Biorthogonal 6.8, Daubechies 10, Haar and Symlets 8). The results show that amongst the Wiener, Average and Median algorithms, the Wiener gave the best results, and amongst the Wavelets (Biorthogonal 6.8, Daubechies 10, Haar and Symlets 8), the Daubechies yielded a better performance. Further, it was also discovered that the combination of Daubechies and Wiener gave better results compared to the individual filters. It is anticipated that future works would involve more experimental work with a variety of ultrasound images of bone fracture.

REFERENCES

Friedland, N., Adam, D., 1989. Automatic ventricular cavity boundary detection from sequential ultrasound images using simulated annealing. *IEEE Trans. Med. Imaging*, 8, Pp. 244–353.

Heiner, J.D., McArthur, T.J., 2010. The ultrasound identification of simulated long bone fractures by prehospital providers. *Wild. Environ. Med.*, 21, Pp. 137–140.

Hubner, U., Schlicht, W., Outzen, S., Michael, H.H., Barthel, 2000. Ultrasound in the diagnosis of fractures in children. *J. Bone Joint Surg. Br.*, 82 (8), Pp. 1170–1173.

Jin, F., Fieguth, P., Winger, L., Jernigan, E., 2003. Adaptive Wiener filtering of noisy images and image sequences, *IEEE Trans.*

Lazovic, D., Wegner, U., Peters, G., Gosse, F., 1996. Ultrasound for diagnosis of apophyseal injuries, *Knee Surg. Sports Traumatol. Arthrosc.*, 3, Pp. 234–237.

Marshburn, T., Legome, E., Sargsyan, A., 2004. Goal-directed ultrasound in the detection of long-bone fractures. *J. Trauma*, 57, Pp. 329–332.

Matlab software version 7.5, The Mathworks, Inc., US [Online]. Available: <http://www.Mathworks.Com>.

Noble, V., Legome, E., Marshburn, T., 2003. Long bone ultrasound, making the diagnosis in remote locations. *J. Trauma*, 54, Pp. 800.

Rathfelder, F.J., Paar, O., 1995. Possibilities for using sonography as a diagnostic procedure in fractures during the growth period. *Unfallchirurg*, 98, Pp. 645–649.

Ultrasound images on bone fracture, Aloka Holding Europe Ag, Switzerland [Online]. Available: <http://www.Ultrasoundcases.Info>.

Yap, M.H., Edirisinghe, E.A., Bez, H.E., 2006. Object boundary detection in ultrasound images, in: Loughborough University, UK, Conference on Computer and Robot Vision.

Zain, M., Luqman, M., Elamvazuthi, I., Begam, K.M., 2009. Enhancement of bone fracture image using filtering techniques. *Int. J. Video Image Process. Netw. Secur., (IJVIPNS)*, 9 (10), Pp. 49–54.

